

# Fatal HLH in a 5 year old girl as a complication of secondary histiocytic sarcoma treated with trametinib and chemotherapy

Aelvoet Y<sup>1,7,\*</sup>, Van Paemel R<sup>1,7,\*</sup>, Hofmans M<sup>2</sup>, Creyten D<sup>3</sup>, Loontjens S<sup>4</sup>, Bautista P<sup>5</sup>, Lissat A<sup>6</sup>, De Moerloose B<sup>7</sup>, Mondelaers V<sup>7</sup>, De Wilde B<sup>7</sup>

<sup>1</sup>Ghent University Hospital, Department of Pediatrics, Ghent, Belgium. <sup>2</sup>Ghent University Hospital, Department of Laboratory Medicine, Ghent, Belgium. <sup>3</sup>Ghent University Hospital, Department of Pathology, Ghent, Belgium. <sup>4</sup>Ghent University Hospital, Cancer Research Institute Ghent and Center for Medical Genetics, Ghent, Belgium. <sup>5</sup>Princes Maxima Centre, Pediatric Hematology-Oncology Unit & Trial and Data Centrum, Utrecht, Netherlands. <sup>6</sup>University Medical Center Freiburg, Division of Pediatric Hematology and Oncology- Department of Pediatrics, Freiburg, Germany. <sup>7</sup>Ghent University Hospital, Department of Pediatric Hematology-Oncology and Stem Cell Transplantation, Ghent, Belgium. \* authors contributed equally

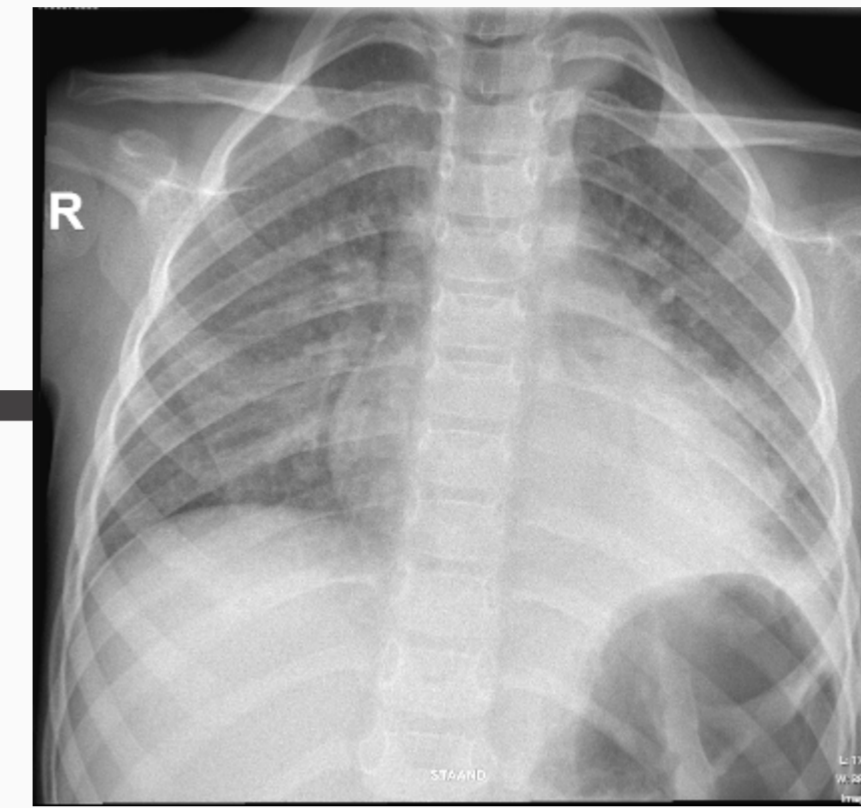
## Background

- **Histiocytic sarcoma (HS)** = rare, aggressive malignancy arising from mature histiocytes
- Challenging diagnosis due to nonspecific clinical presentation, often mimicking infections or systemic disorders
- No randomized clinical trials in children
- Local resection w/ radiotherapy if solitary lesions
- Chemotherapy in disseminated disease
- Targeted therapy if targetable mutations
- Poor prognosis if secondary to a hematological malignancy

## Case report

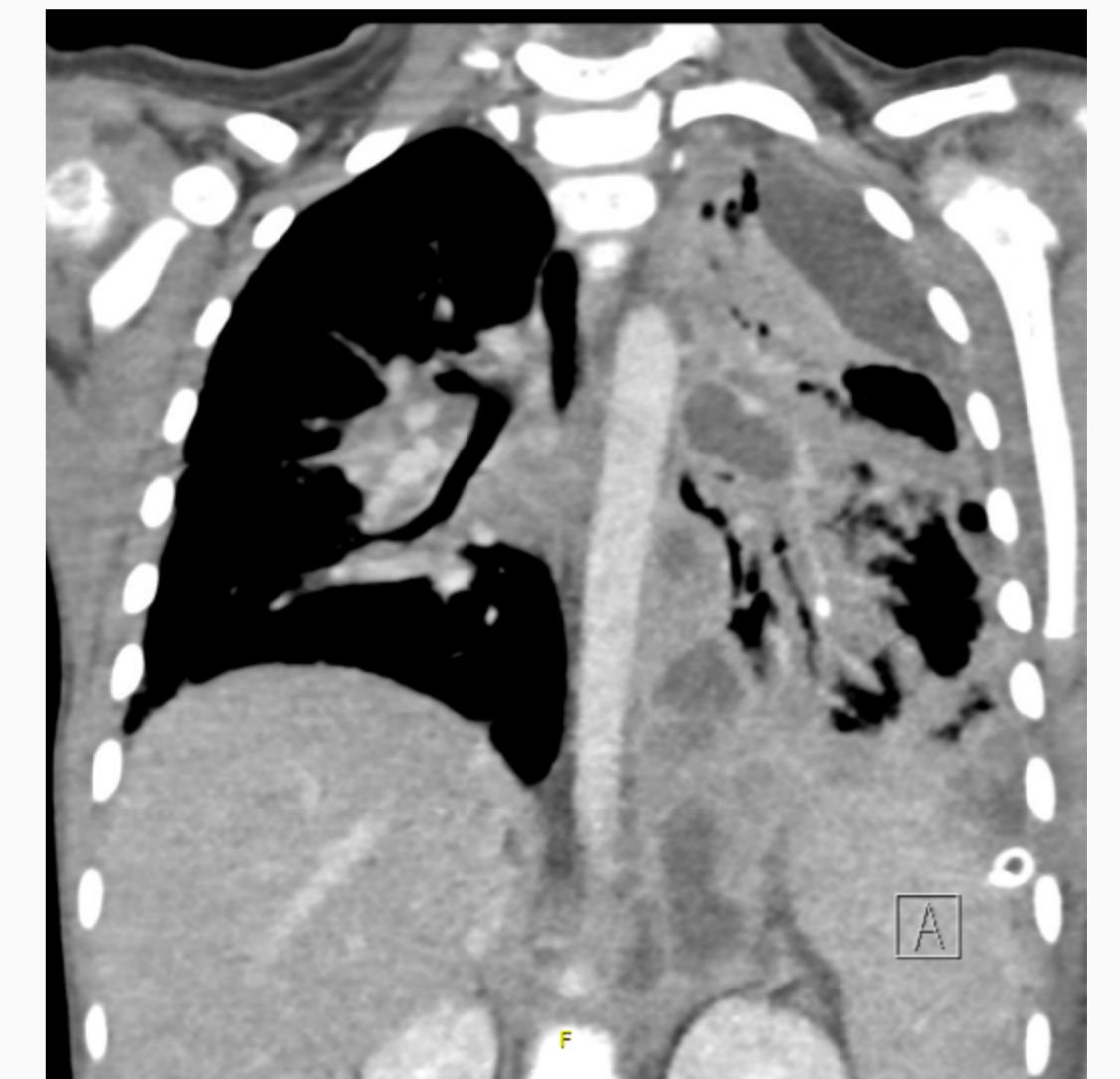
5 year old girl with T-ALL  
ALLtogether, IR low risk  
in maintenance phase

D410 T-ALL



Clinical deterioration despite IV antibiotics and antifungal therapy

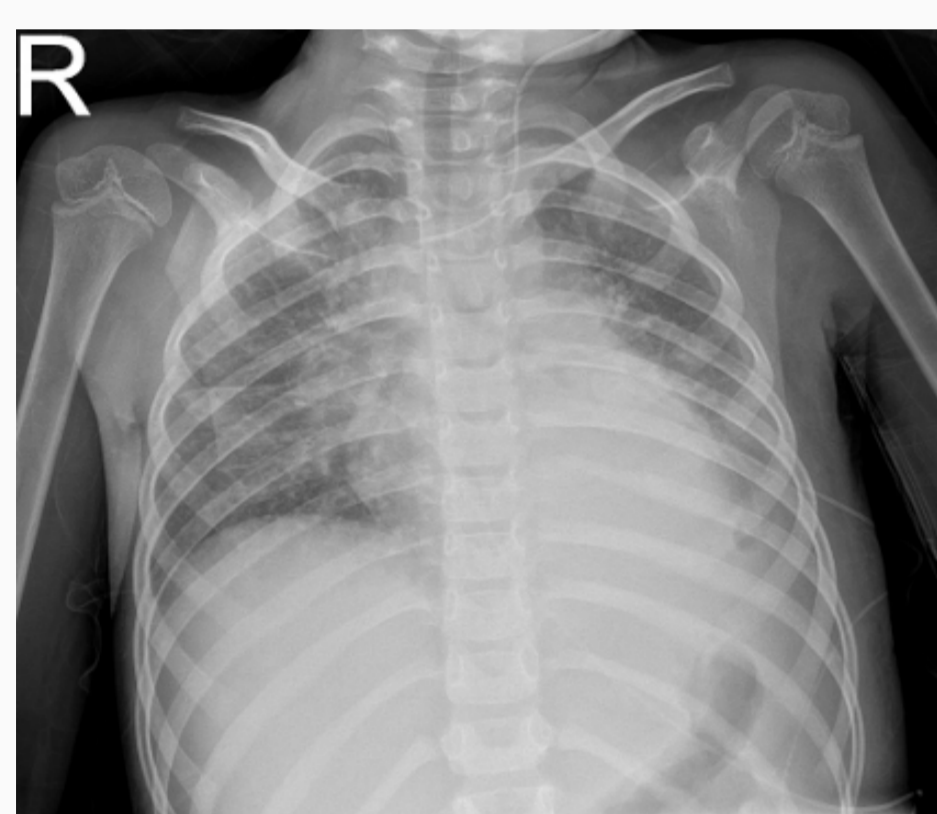Fever + malaise + left sided chest pain, elevated inflammatory markers, mild thrombocytopenia and a left shifted leukocyte count



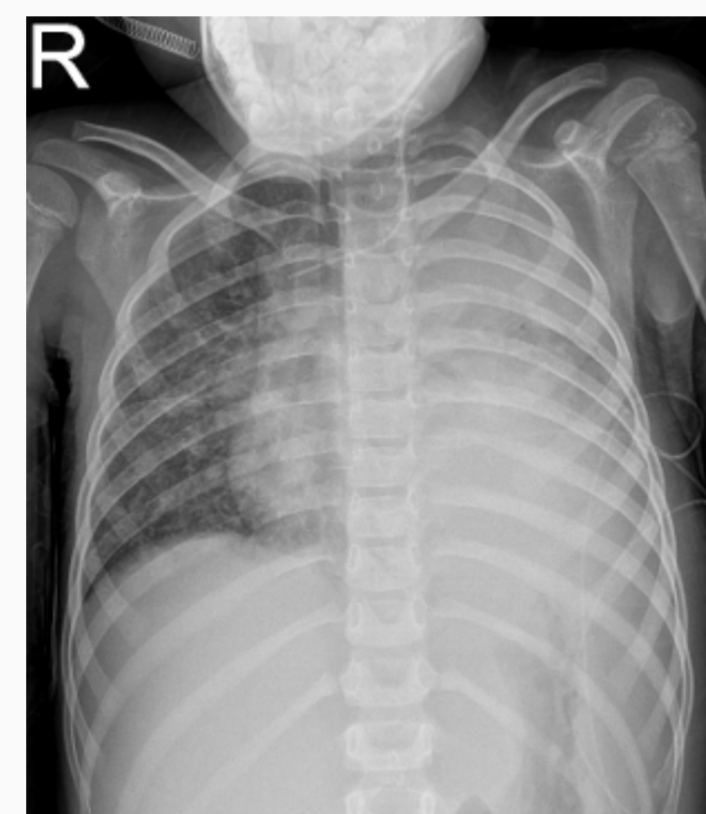D443 T-ALL  
D0 HS

Necrotizing left-sided pleuropneumonia on CT-scan

Video-assisted thoracoscopy (VATS) showing fibrinous mass



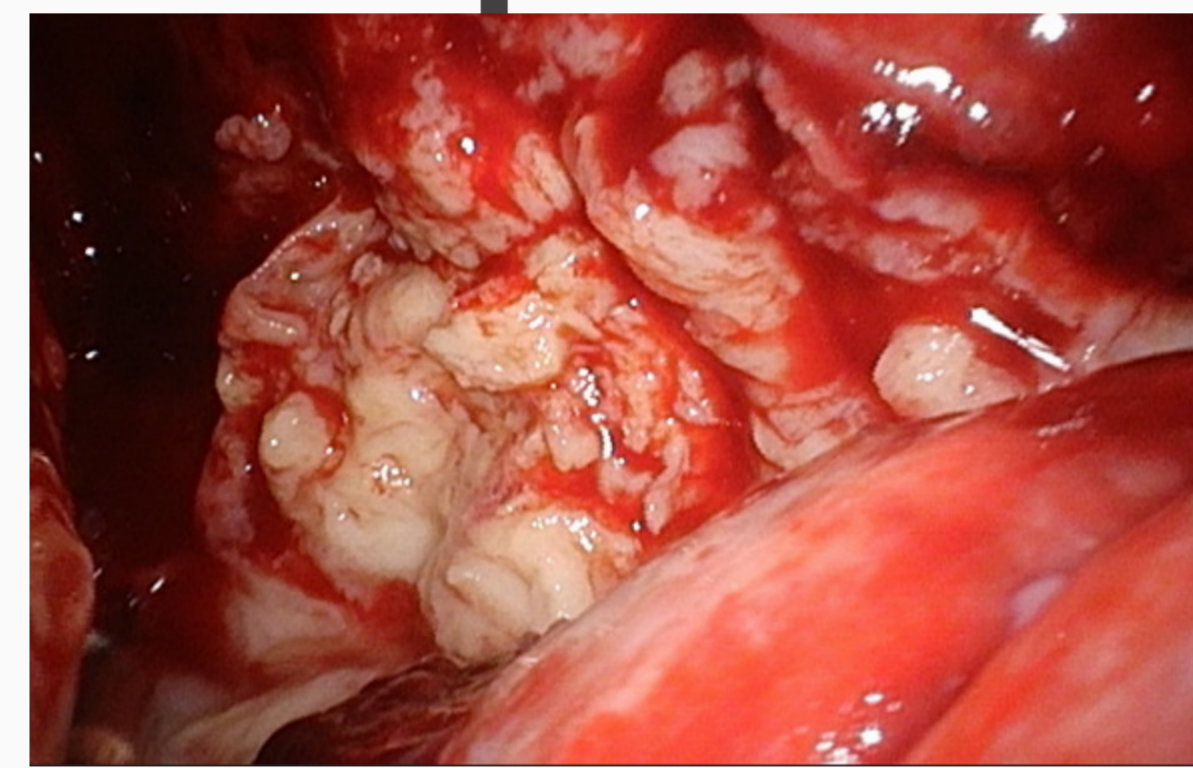
Good response  
48h after IVA



Before IVA

D7

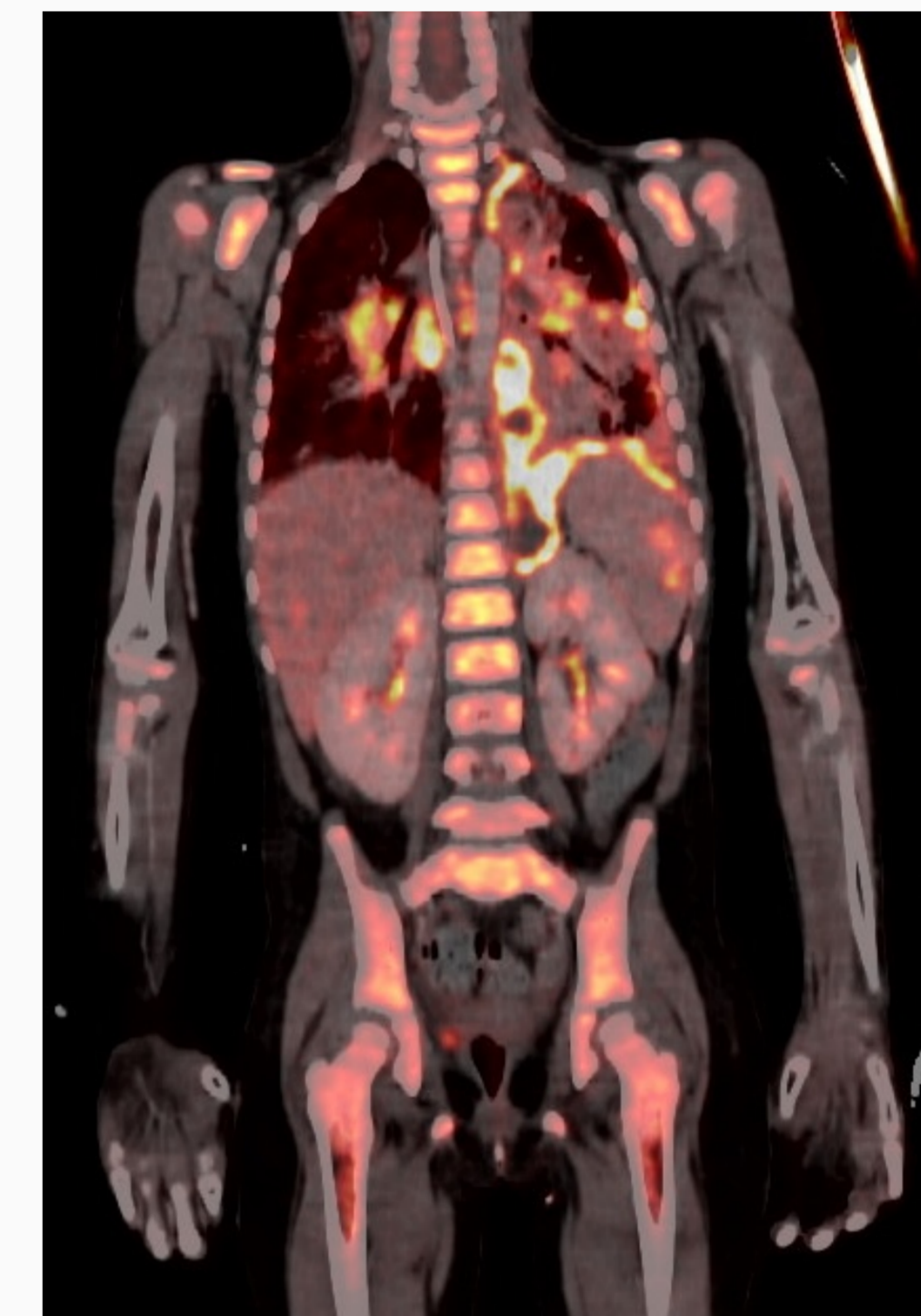
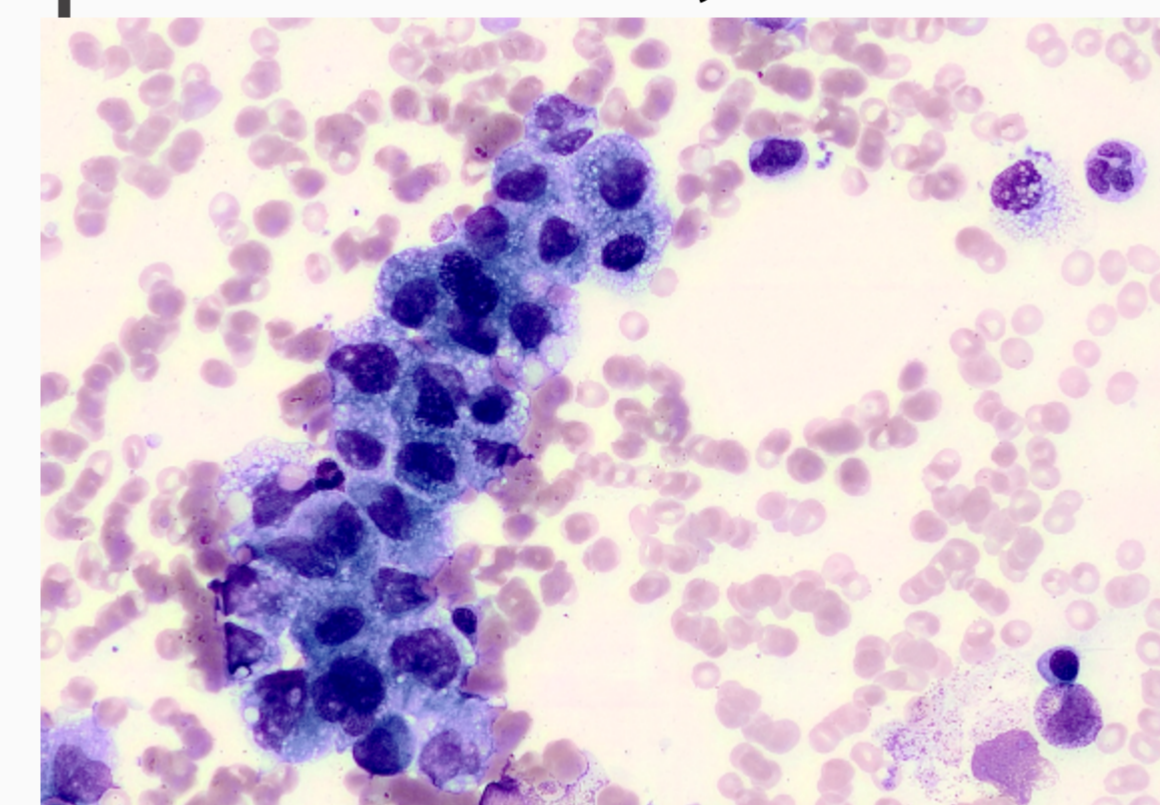
Respiratory deterioration on PICU, imminent intubation, malignant cells in pleural effusion NOS



## Comprehensive work-up pleural effusion

- Extensive microbial, viral and fungal testing negative
- IHC: high-grade malignant proliferation & strong expression of CD68, CD163, CD45, CD4, suggesting **histiocytic sarcoma**
- Genomic alterations in **MAPK pathway** (BRAF, KRAS)
- Disappearance of an initial NRAS mutation from the T-ALL
- TCR gene rearrangement analysis showed **clonal relationship** with T-ALL

Bone marrow biopsy showing clusters of histiocytic sarcoma

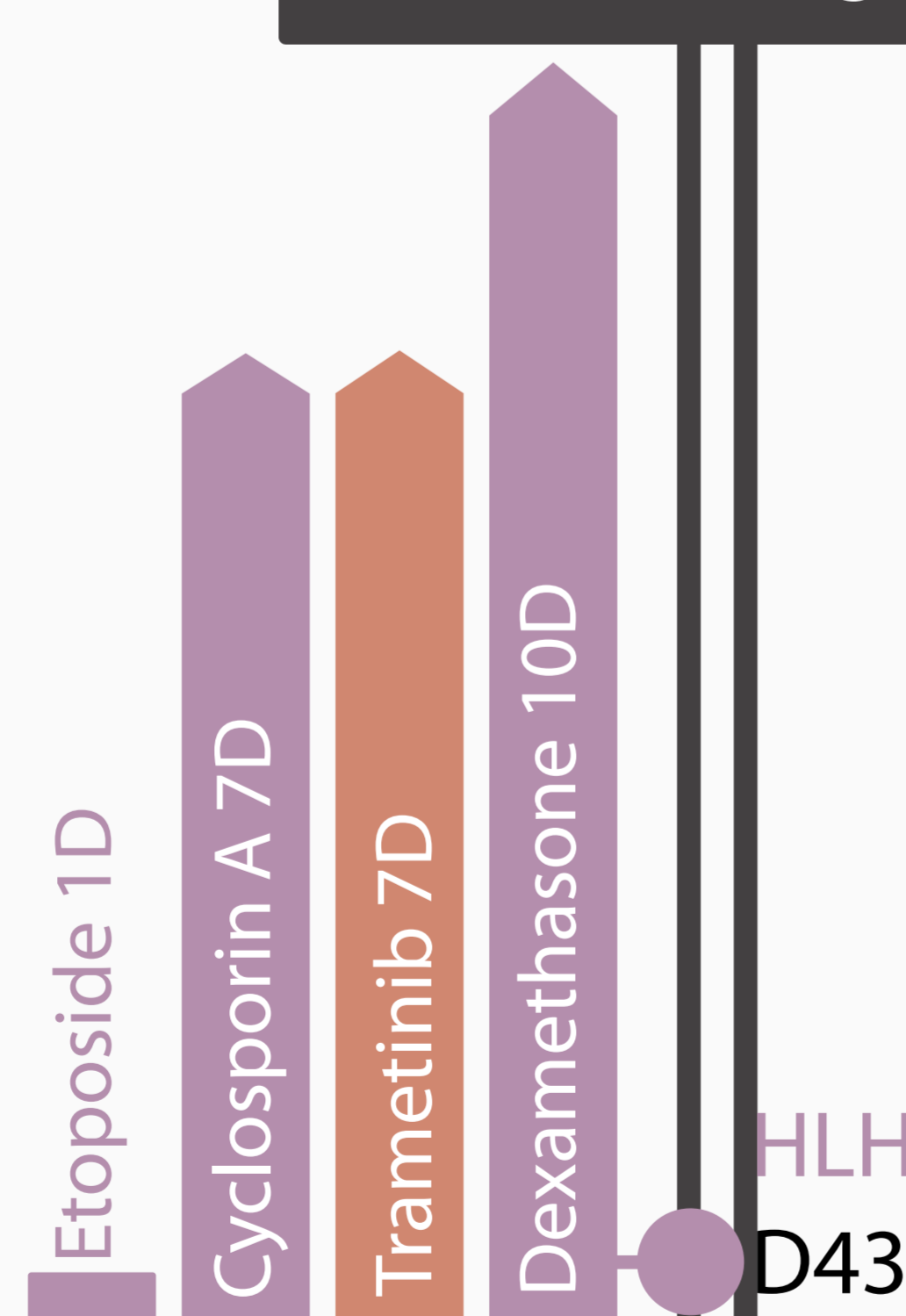


**Staging** shows metastatic disease with lymphangitis carcinomatosa, diffuse lymphadenopathy, liver lesions and bone marrow invasion

## Conclusions

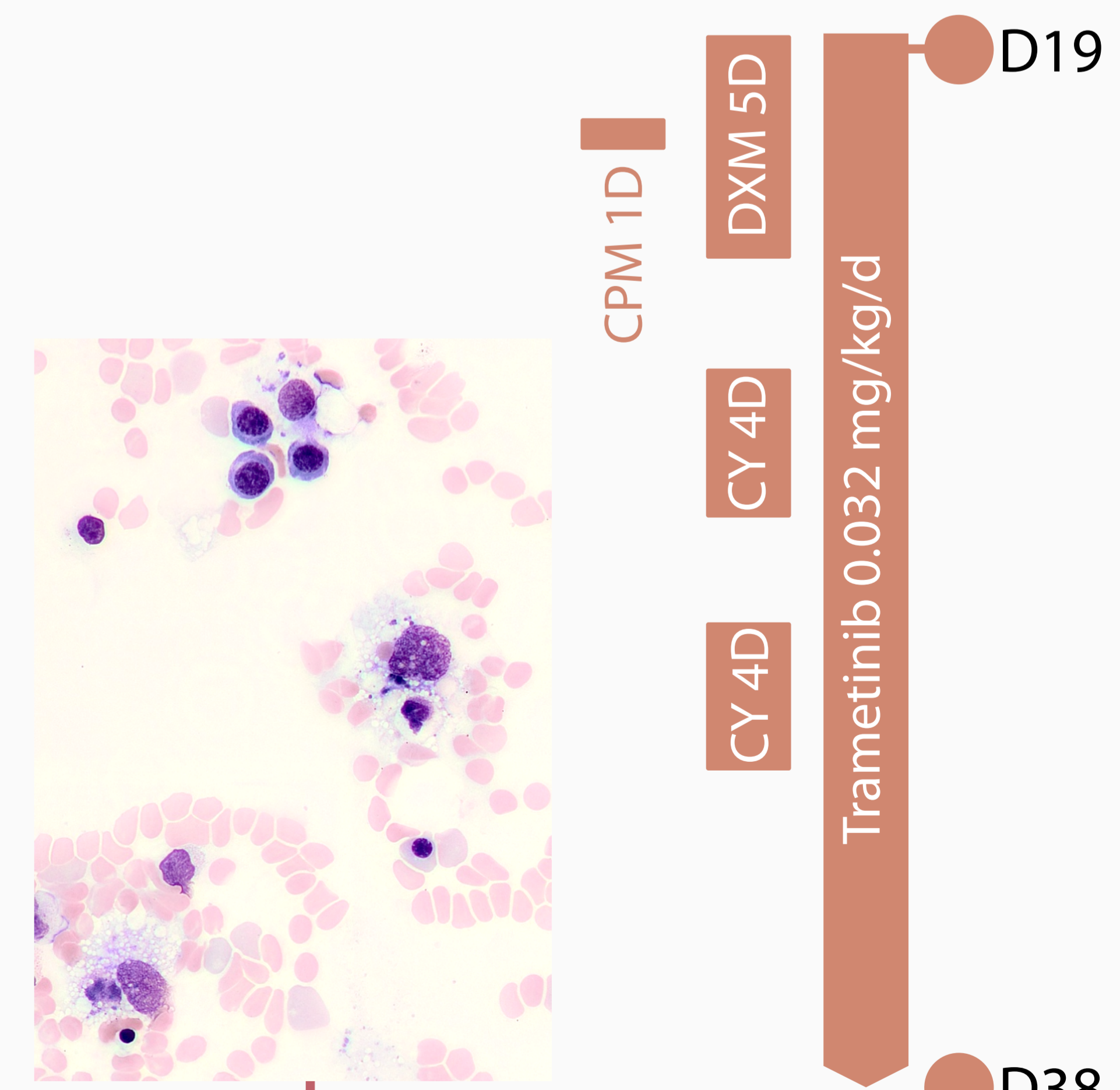
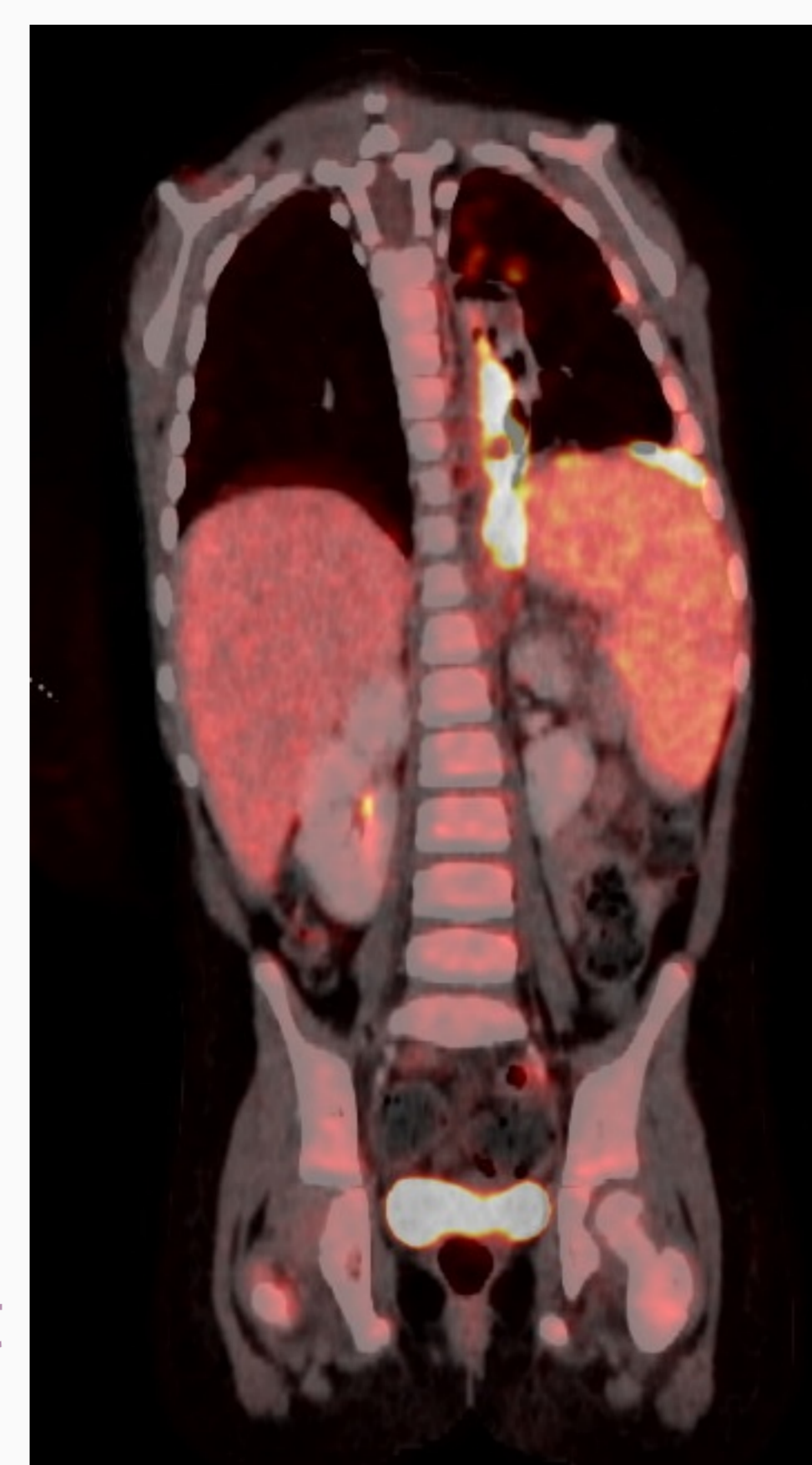
- Necrotizing pleuropneumonia as a rare presentation of histiocytic sarcoma
- T-ALL clone transdifferentiation with the same TCR rearrangement
- Accumulation of multiple MAPK pathway mutations
- Favourable tumor response during treatment with trametinib
- HLH as a complication of disease progression and/or due to treatment-induced maturation of histiocytic cells?
- Classic HLH treatment proven ineffective

D53 - death due to overwhelming HLH



HLH treatment

D43



**HLH diagnosis supported by bone marrow evaluation, PET-CT and blood work-up**  
Daily transfusion needed for platelets and erythrocytes  
Soluble CD25 21000 pg/mL  
Ferritin 1200 µg/L - hepatosplenomegaly

D40 - 42: **PET-CT** showing **partial response** on the primary site and hypermetabolic activity in spleen and liver, **bone marrow** showing **numerous histiocytes** without atypical characteristics